

Essure® Permanent Birth Control System (Conceptus Incorporated, San Carlos, Calif) is a minimally invasive, nonincisional alternative for women seeking sterilization. **Essure** micro-insert placement procedure can be performed in an outpatient or office surgery setting. Using a transcervical approach, an **Essure** micro-insert is placed in the proximal portion of each fallopian tube where it expands and anchors itself. The **Essure** micro-insert induces a local, benign fibrous tissue ingrowth from the surrounding tubal walls.¹ This tissue ingrowth completely occludes the fallopian tube within 3 months, resulting in sterilization. The effectiveness and safety of the **Essure Permanent Birth Control System** was demonstrated in clinical trials in 632 women who relied on **Essure** for contraception for 12 or more months.^{2,3} The following is a case study from one of those clinical trials.

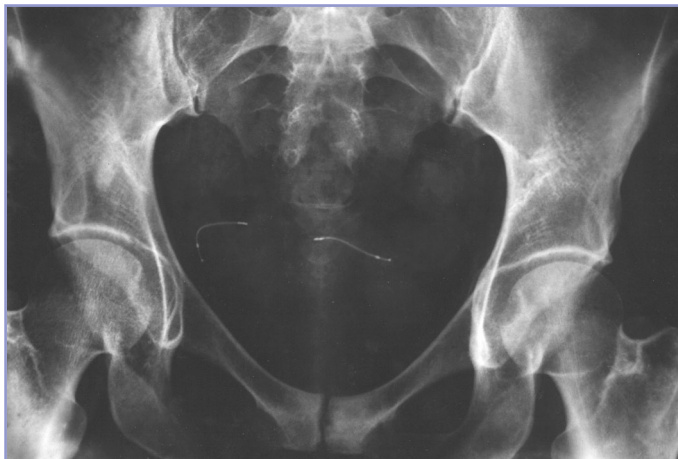Case Study 2

Presentation: A 32-year-old Caucasian female presents requesting sterilization, but states that she wants to avoid general anesthesia.

Medical History: The gynecology history is unremarkable and a history of regular menses exists. This woman has had 3 children, and all 3 births were live and vaginal. Her previous method of contraception was condoms. Currently, she is employed part-time as a commercial agent.

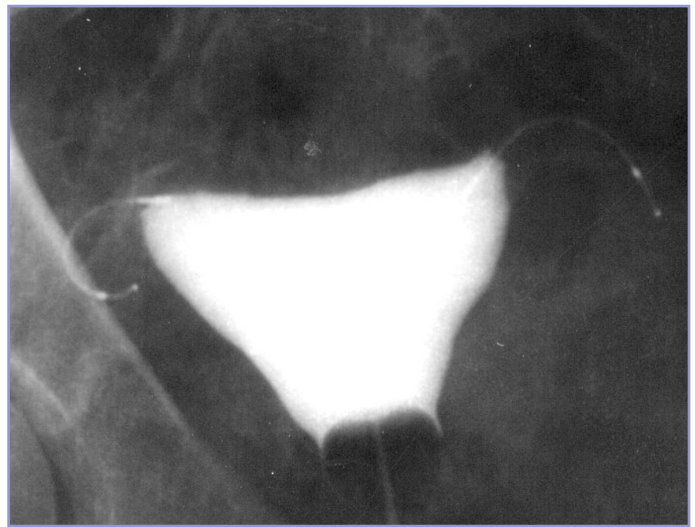
Physical Examination: Test results for *Neisseria gonorrhoea* and *Chlamydia trachomatis* are negative; urine pregnancy test is negative; hemoglobin and WBC count are within normal ranges. Weight is 56 kg; position of uterus is anteverted; no pelvic pathology exists; cycle day is 10.

Preprocedure: Prior to **Essure** micro-insert placement, 775 mg of naproxen sodium and 10.0 mg of diazepam were given by mouth. A paracervical block was placed using 16 mL bupivacaine injected at 12, 3, and 9 o'clock positions.



1-year x-ray

Procedure: With the individual in the lithotomy position, pump-feed saline (warmed to 37°C) irrigation was used to gently dilate the cervix and provide forward vision for the hysteroscope. Under hysteroscopic visualization (Olympus 5.5 mm), an **Essure** micro-insert was inserted first into the proximal portion of the left and then the proximal portion of the right fallopian tube. After placement, 4-mm and 6-mm trails were observed on the right and left tube, respectively. No adverse events and no pain accompanied the procedure. Insertion of the **Essure** micro-inserts was accomplished in 5 minutes.



3-month hysterosalpingogram

Postplacement: Recovery was uneventful; no medications were needed; satisfactory placement of the micro-inserts was confirmed by pelvic x-ray; discharge occurred 30 minutes after the procedure.

Follow-up: On day 1, normal activities were resumed and the individual returned to work. At 3 months, total occlusion was shown by hysterosalpingogram. At 18 months, **Essure** micro-inserts continued as the method of contraception. When asked to rate average comfort with device wearing as excellent, very good, good, fair, or poor, response was "excellent."

NOTE: This is a single-case study and may not represent typical results.

This case was performed by Enrique Cayuela Font, MD, and Federico Heredia, MD, Spain.

References

1. Valle RF, Carignan CS, Wright TC. Tissue response to the STOP microcoil transcervical permanent contraceptive device: results from a pre hysterectomy study. *Fertil Steril.* 2001;76:974-980.
2. Kerin JF, Carignan CS, Cher D. The safety and effectiveness of a new hysteroscopic method for permanent birth control: results of the first Essure pbc clinical study. *Aust N Z J Obstet Gynaecol.* 2001;41:364-370.
3. Valle RF, Cooper JM, Kerin JF. Hysteroscopic tubal sterilization with the Essure nonincisional Permanent Contraception System. *Obstet Gynecol.* 2002;99(suppl):11S.