

T-Sling: Transobturator Approach

Surgeries performed by:

Dr. Red Alinsod

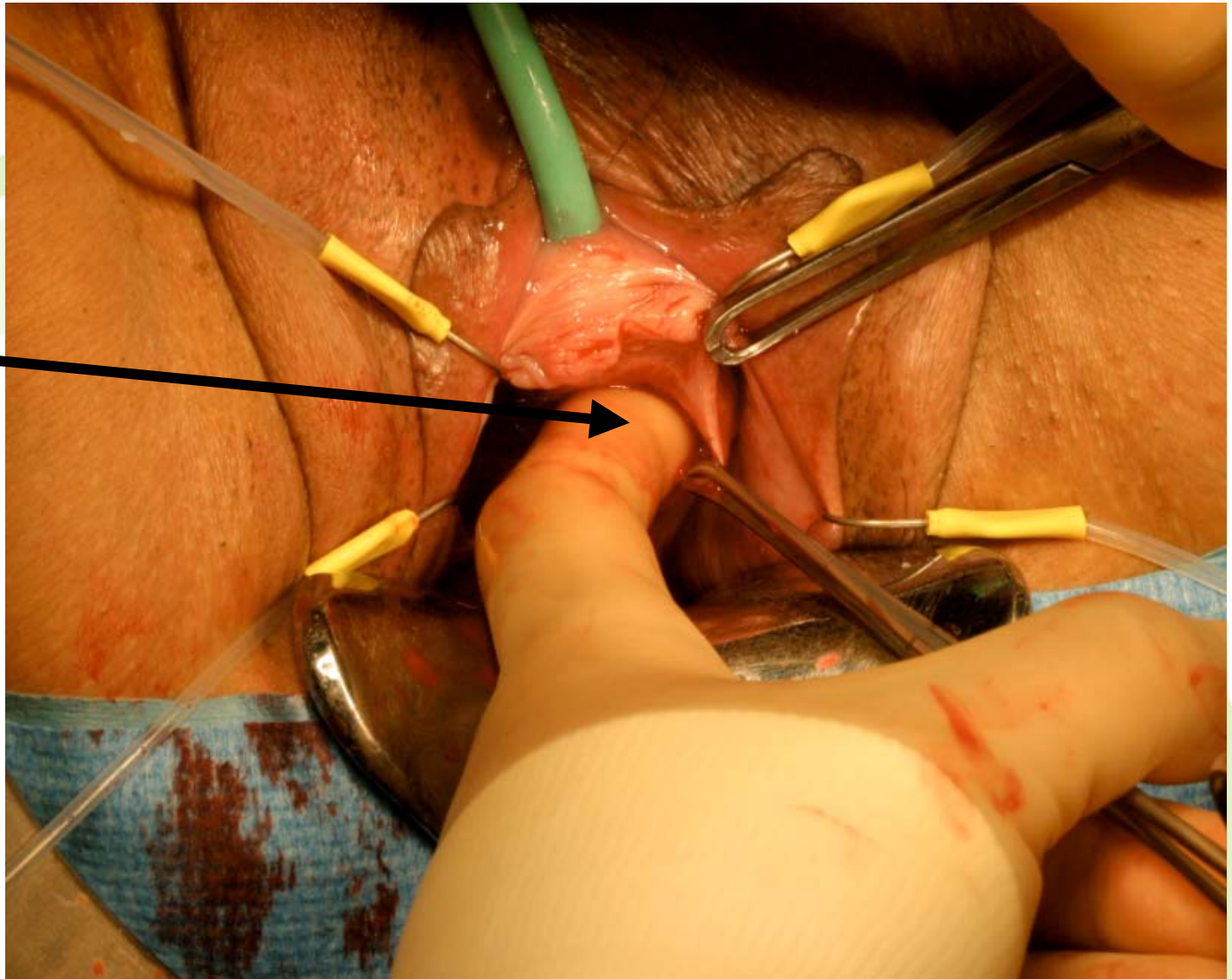
Urogynecology & Pelvic Surgery

Facey Medical Group

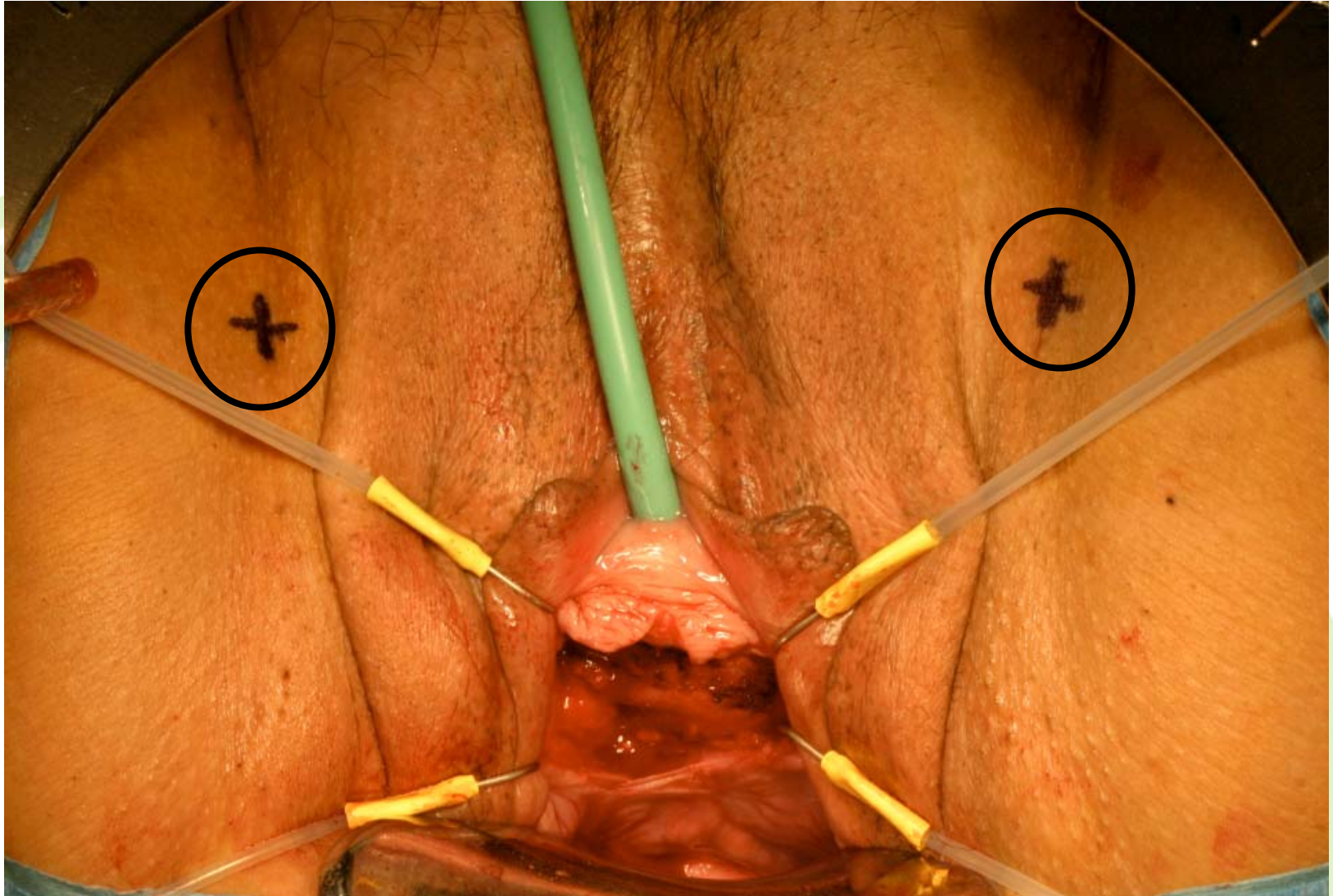
Northridge, CA

View of open anterior vaginal dissection

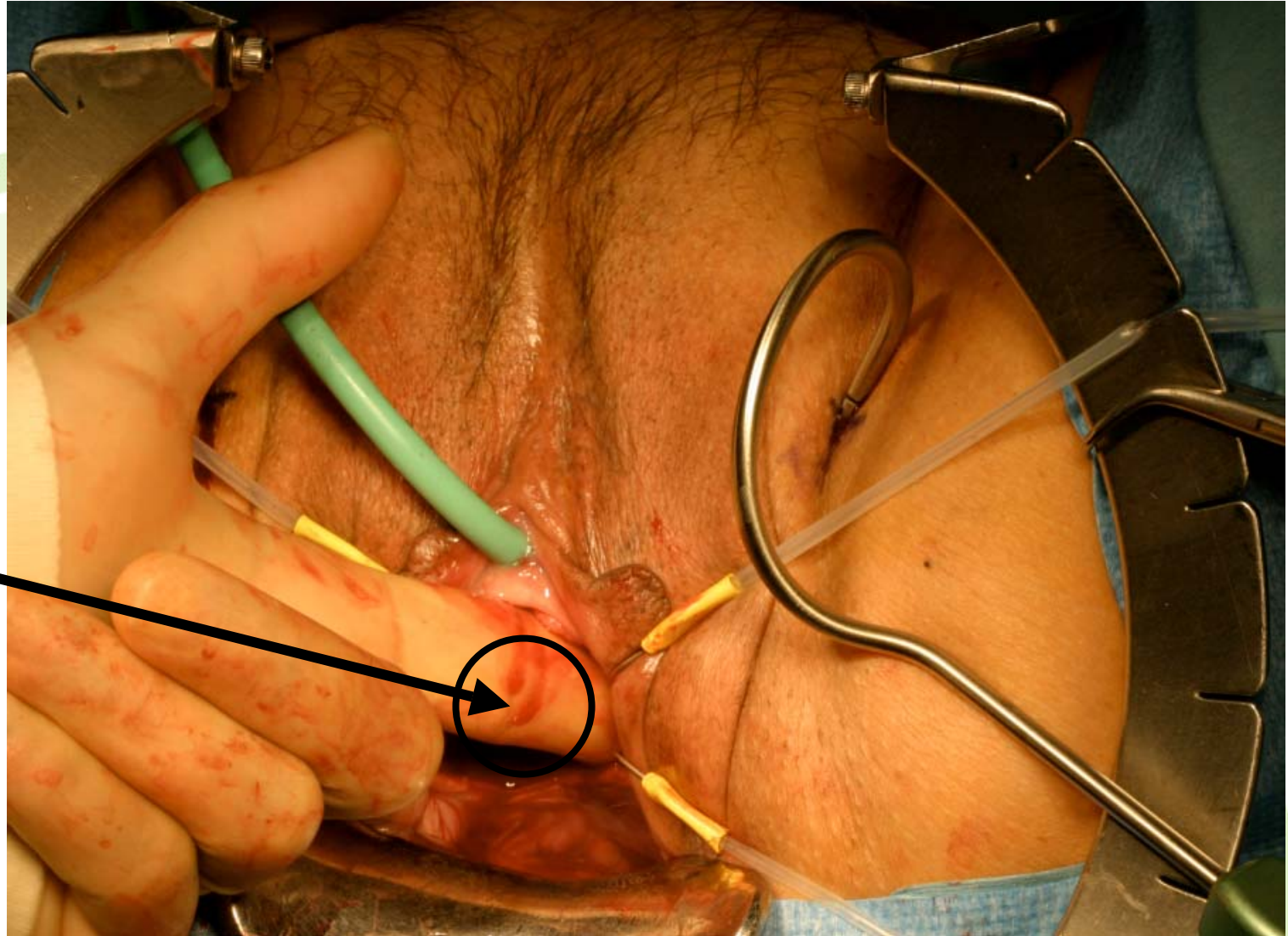
In addition to sharp dissection, blunt finger dissection is performed



Incision sites for introducers



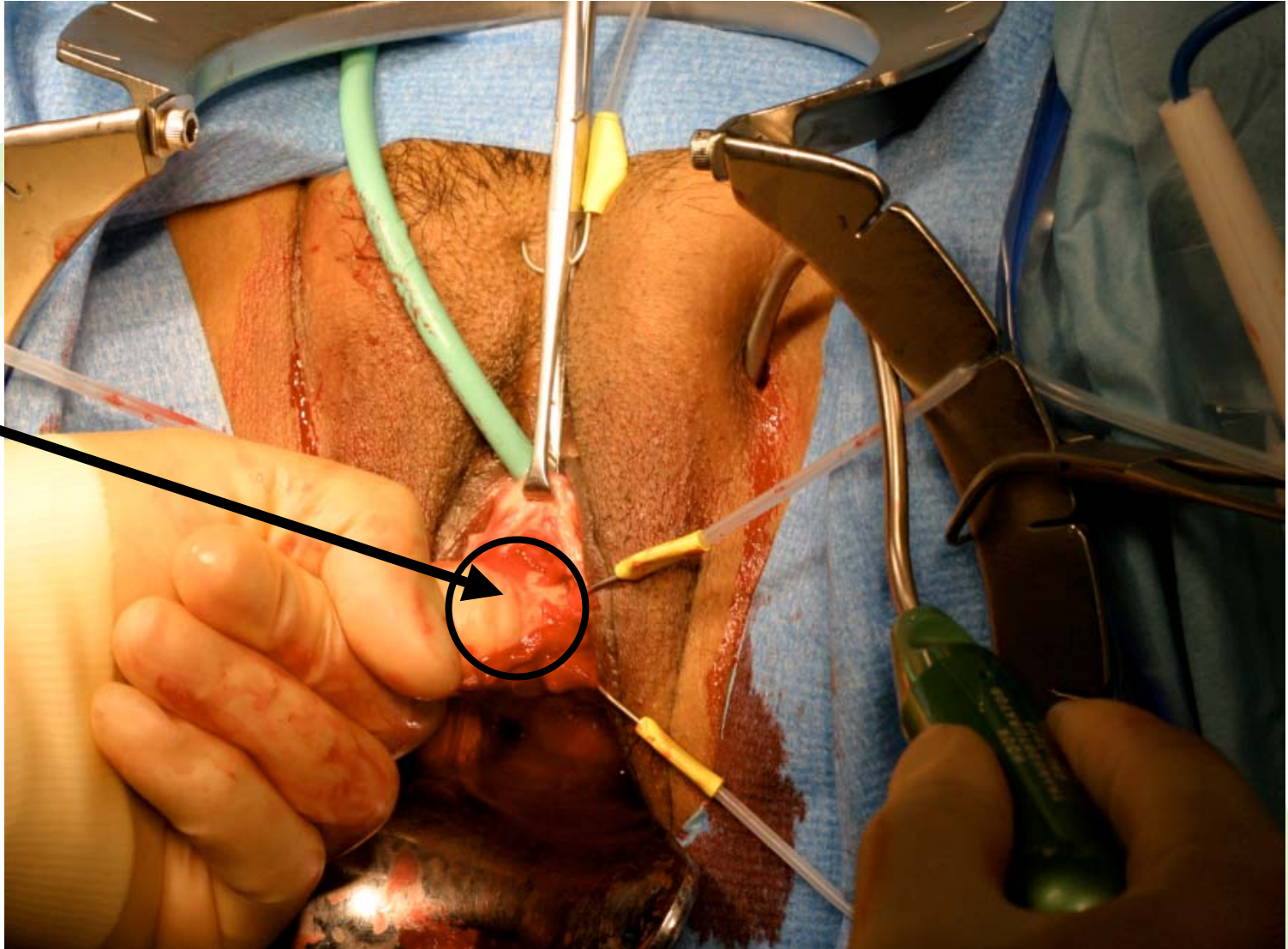
Insertion of introducer-Helical



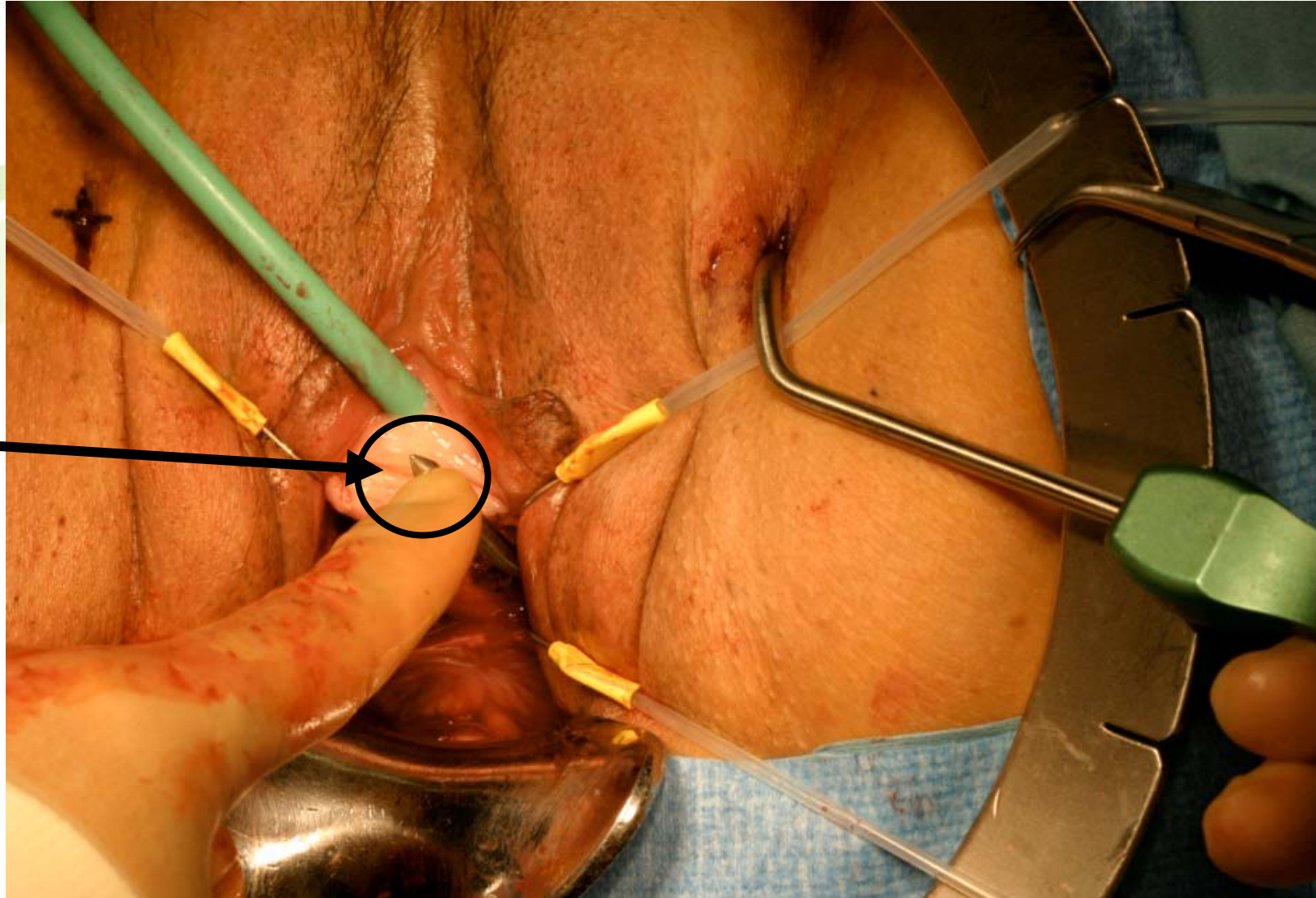
Introducer
tip will
reappear
here, through
anterior
vaginal
dissection

Insertion of introducer-Hook

Finger is inserted into the dissection to meet the introducer tip as it comes through the foramen, **minimizing blind passage**



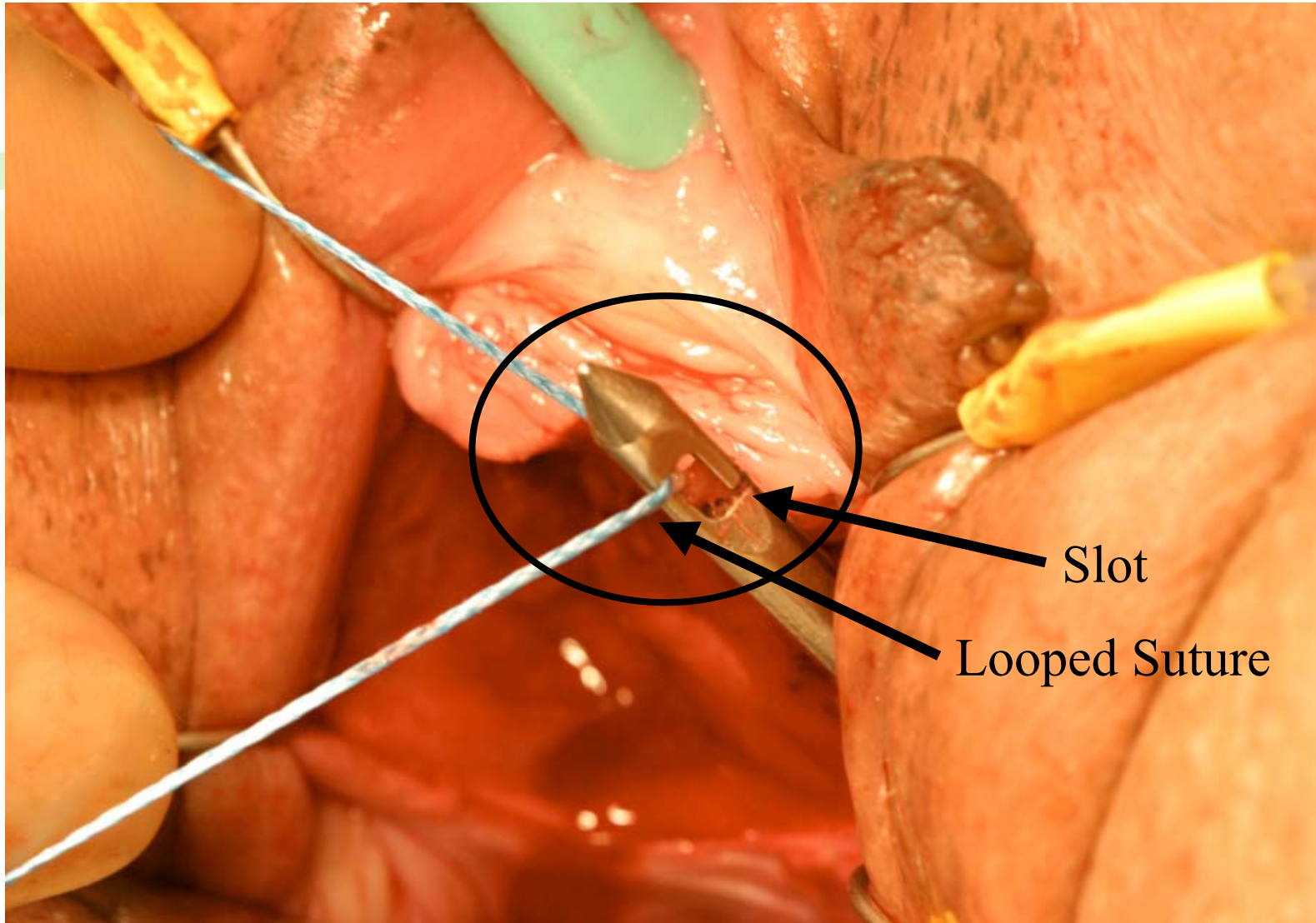
Full insertion of introducer



Introducer
tip

Connection of T-Sling to Introducer

Looped suture is placed through slot, allowing for a secure hold, with no need for wide plastic connectors

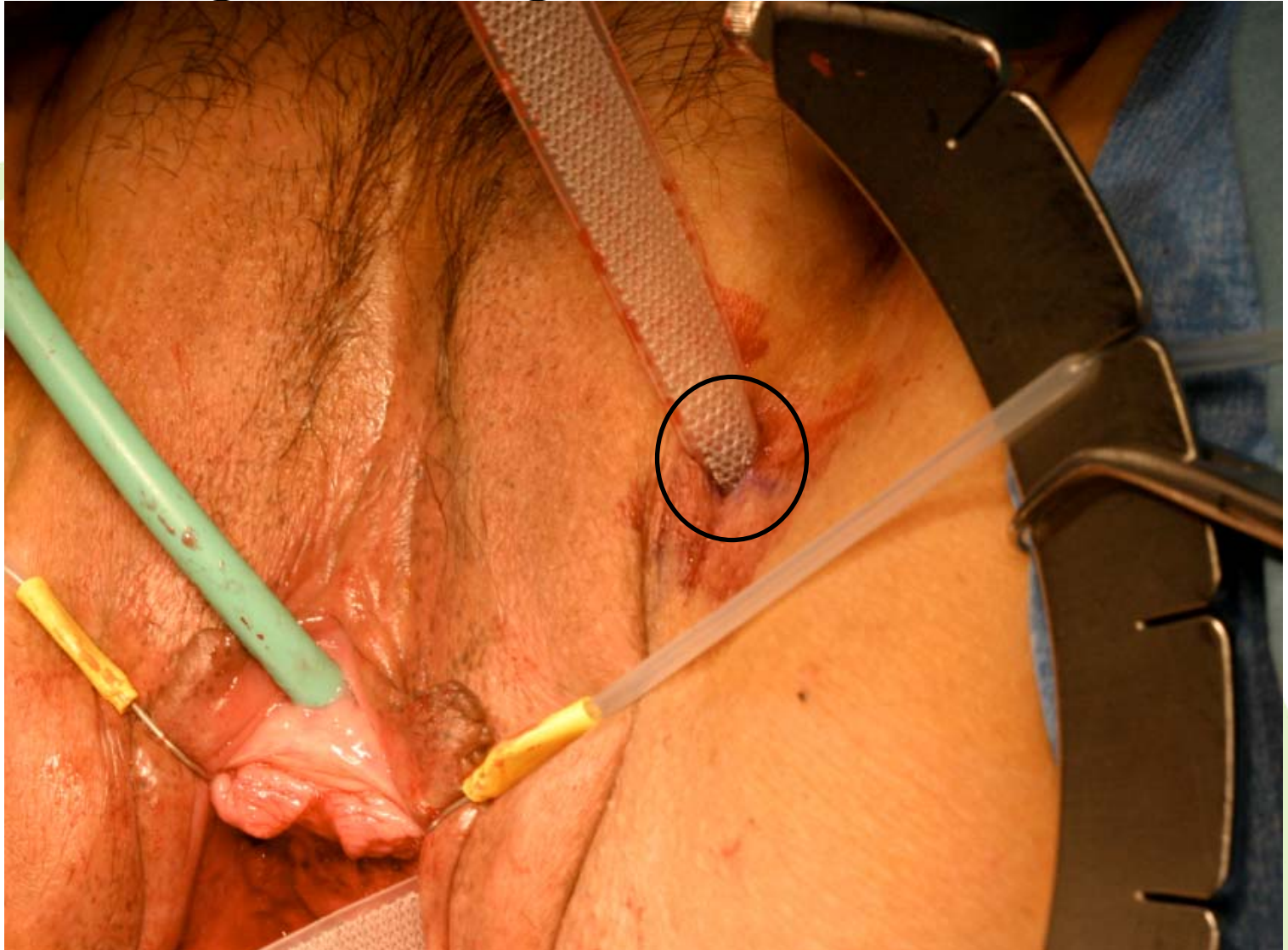

Slot

Looped Suture

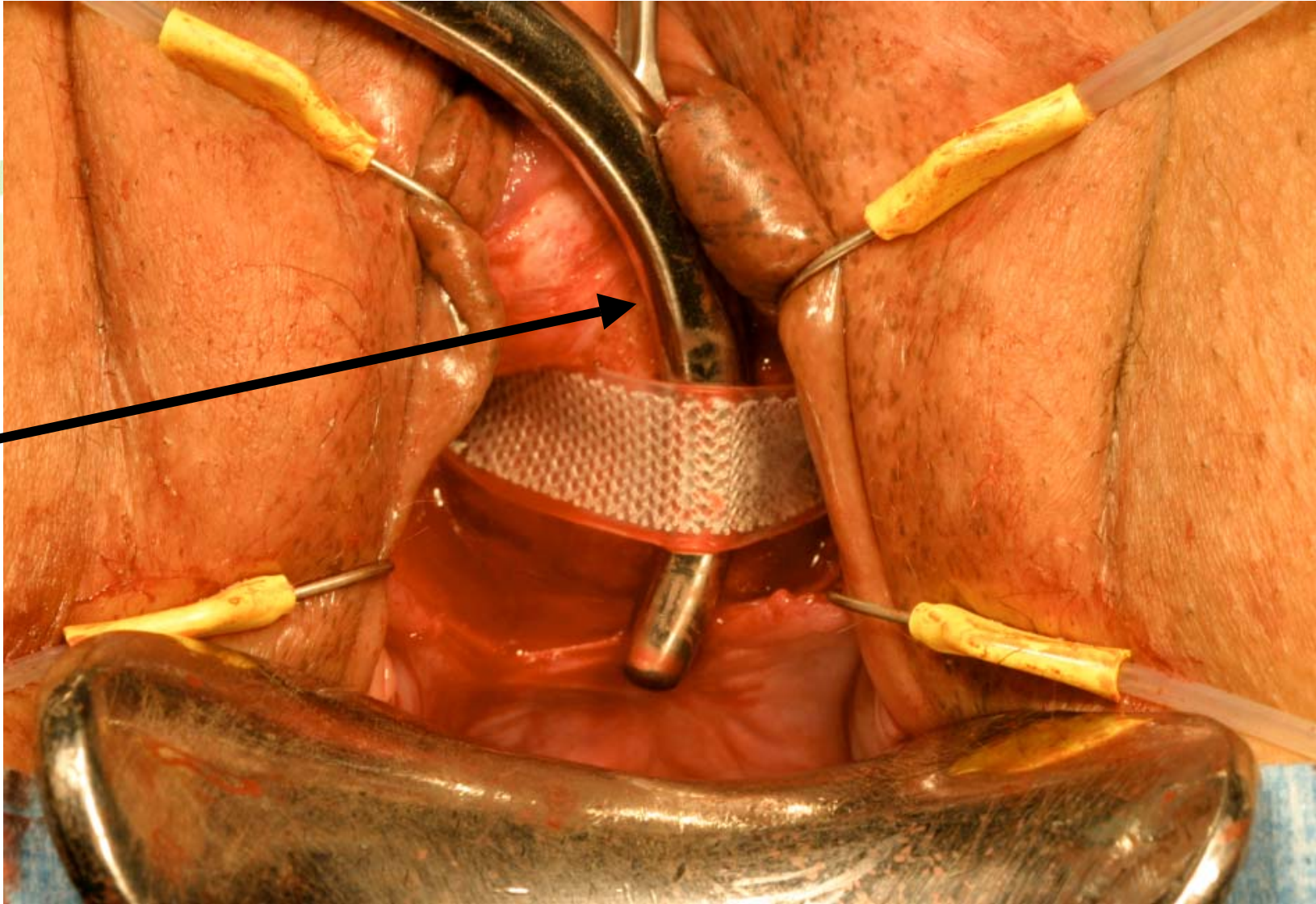
Sling exiting the incision

T-Sling is pulled through thigh incisions




Tensioning sling under urethra

A dilator, finger, or other tensioning instrument is held between the sling and the urethra for optimal tension adjustment

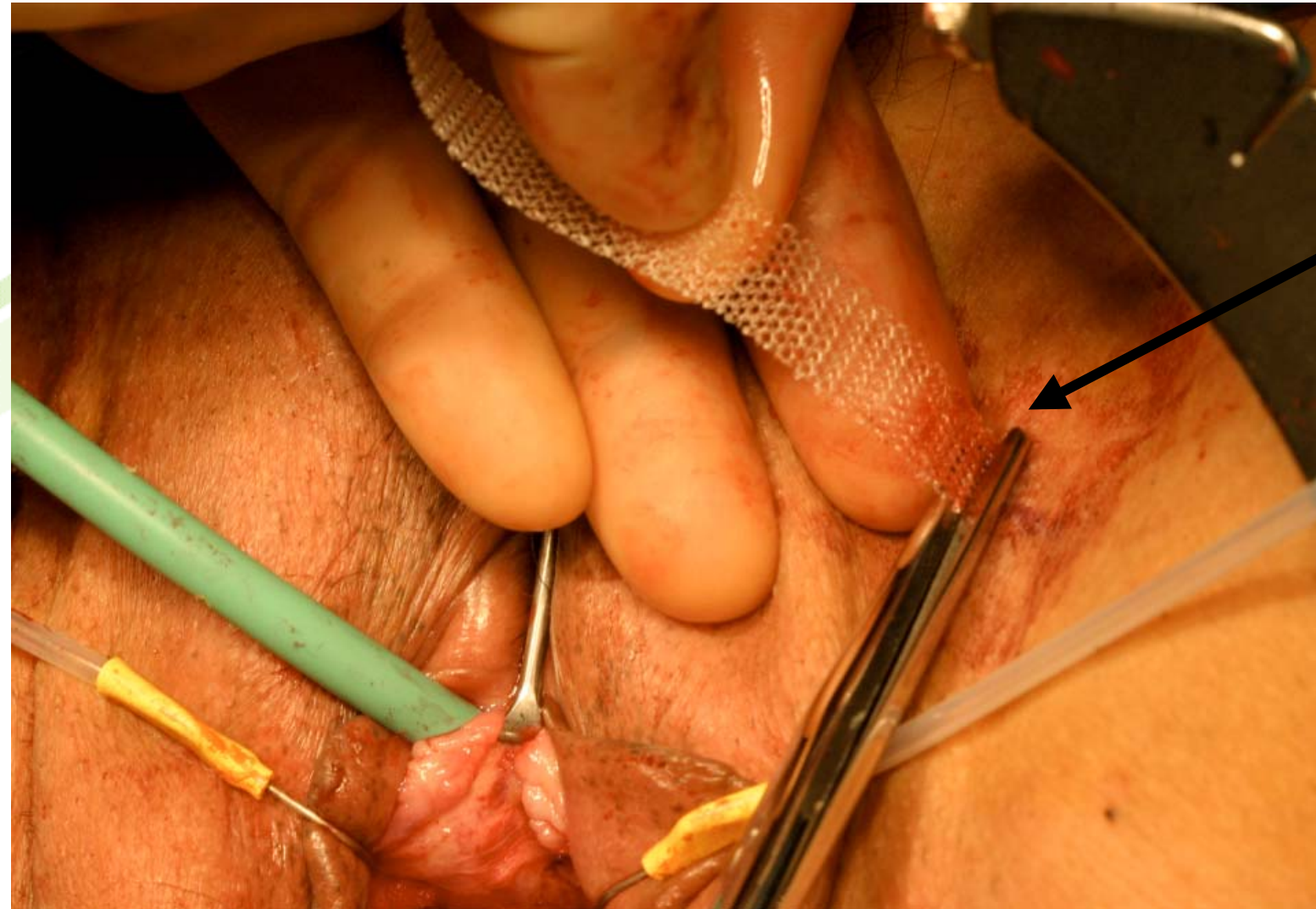


Sleeve Removal



Once sling has been tensioned, a grasper is used to remove both sleeves

Trimming sling at incision site



The sling is trimmed at the incision site. Dermabond or Steri-Strips can be placed on the incision.